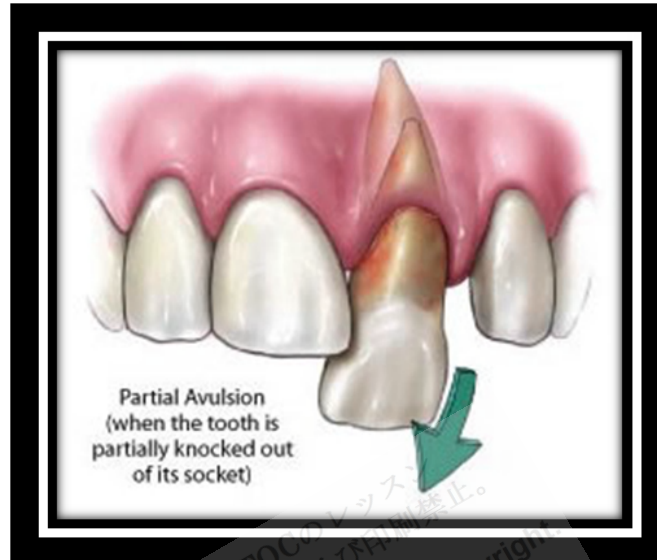


# Fractured and Avulsed Teeth



[http://idealdentalcare.in/images/avulsed\\_tooth.jpg](http://idealdentalcare.in/images/avulsed_tooth.jpg)

**Tooth fracture:** Fractures are divided by depth into those that

- Affect only the enamel
- Expose the **dentin**
- Expose the **pulp**

If the fracture involves only the **enamel**, patients notice rough or sharp edges but are otherwise **asymptomatic**. Dental treatment to smooth the edges and improve appearance is elective.

If dentin is exposed but not the dental pulp, patients usually exhibit sensitivity to cold air and water. Treatment is a mild analgesic and referral to a dentist. Dental treatment consists of restoration of the tooth by a **composite** (**white filling**) or, if the fracture is extensive, a dental crown, to cover the exposed dentin.

If the pulp is exposed (indicated by bleeding from the tooth) or if the tooth is mobile, dental referral is urgent. Dental treatment usually involves a root canal.

**Root fractures** and **alveolar fractures** are not visible, but the tooth (or several teeth) may be mobile. Dental referral is also urgent for stabilization

by bonding an **orthodontic arch wire** or **polyethylene** line onto several adjacent teeth.

**Tooth avulsion:** Avulsed primary teeth are not replaced because they typically become necrotic, then infected. They may also become **ankylosed** and do not **exfoliate**, thereby interfering with the eruption of the permanent tooth.

If a secondary tooth is **avulsed**, the patient should replace it in its socket immediately and seek dental care to stabilize it. If this cannot be done, the tooth should be kept immersed in milk or wrapped in a moistened paper towel and brought to a dentist for replacement and stabilization. The tooth should not be scrubbed, because scrubbing may remove viable **periodontal ligament fibers**, which aid in reattachment. A patient with an **avulsed** tooth should take an antibiotic for several days. If the avulsed tooth cannot be found, it may have been aspirated, embedded in soft tissue, or swallowed. A chest x-ray may be needed to rule out aspiration, but a swallowed tooth is harmless.

A partially avulsed tooth that is repositioned and stabilized quickly usually is permanently retained. A completely avulsed tooth may be permanently retained if replaced in the socket with minimal handling within 30 min to 1 h. Both partial and complete **avulsions** usually ultimately require root canal therapy because the pulp tissue becomes necrotic. When replacement of the tooth is delayed, the long-term retention rate drops, and root **resorption** eventually occurs. Nevertheless, a patient may be able to use the tooth for several years.

### Key Points

- Tooth fracture that exposes dentin but not pulp can be treated with a filling or sometimes a dental crown.
- Tooth fracture that exposes the pulp will likely require a root canal.
- An avulsed primary tooth is not replaced.
- An avulsed secondary tooth is gently rinsed (but not scrubbed) and immersed in milk or a wet paper towel for transport to a dentist for replacement in the socket.
- Avulsed teeth that are quickly replaced are often retained but ultimately most likely will require a root canal.

**Reference:** <http://www.merckmanuals.com>